

## Giant prostatic urethral stones in a young patient

Stone diseases

Aydemir Asdemir<sup>1</sup>, Huseyin Saygin<sup>2</sup>, Esat Korgali<sup>2</sup>, Tugba Yildiz Asdemir<sup>3</sup>

<sup>1</sup>Urology Clinic, Suluova Public Hospital, Amasya

<sup>2</sup>Department of Urology, Faculty of Medicine, Cumhuriyet University, Sivas

<sup>3</sup>Department of Old Care, Sabuncuoglu Serefeddin Vocational School Of Health Services , Amasya University, Amasya, Turkey

*This article's abstract was presented on 5. Congress of Urologic Surgery (2020/11/7-15, online, e-voiced presentation, E-SB-44, page 257).*

### Abstract

Giant prostatic urethral stones have been reported as a very rare entity, and the etiology of these stones is not clear. Here we report a case of a 44-year-old man with giant multiple prostatic urethral stones presented with voiding difficulty and recurrent urinary tract infections. A big stone in the right cavity was observed endoscopically, some of them protruding into the urethra, and two other big stones in the left cavity were observed after resection of the surface tissue on the stones on the prostate. Following cystoscopy, giant prostatic stones were removed endoscopically after holmium-YAG laser lithotripsy.

### Keywords

Giant; Prostate; Urethra; Stone

DOI: 10.4328/ACAM.20394 Received: 2020-11-06 Accepted: 2020-12-14 Published Online: 2020-12-27 Printed: 2021-06-15 Ann Clin Anal Med 2021;12(Suppl 2): S233-235

Corresponding Author: Aydemir Asdemir, Urology Clinic, Suluova Public Hospital , 05500, Amasya, Turkey.

E-mail: aydemirasdemir@hotmail.com P: +90 5068943216

Corresponding Author ORCID ID: <https://orcid.org/0000-0002-9141-6727>

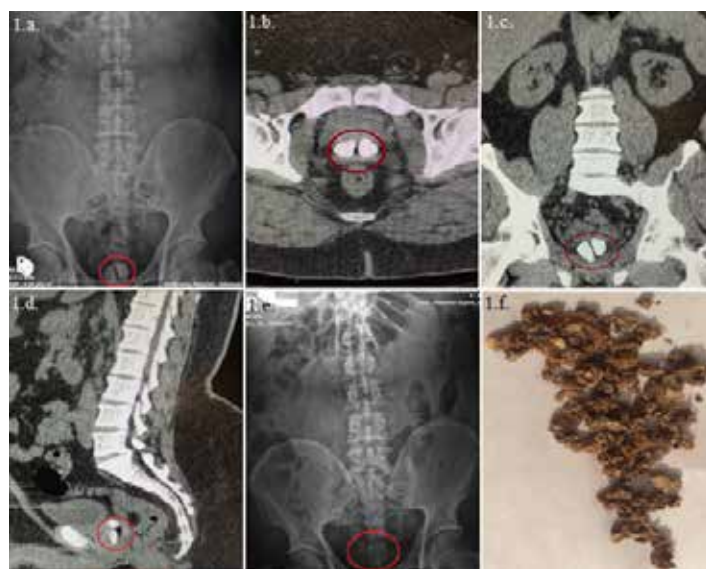## Introduction

Even though giant prostatic urethral stones are reported to be common in elderly men, they are quite exceptional to be encountered in younger adults. Prostatic parenchymal calculi are very common and consist of calcified corpora amylacea usually incidental, findings on computed tomographic (CT) scan or transrectal ultrasound. As reported their incidence increase with age, they are often rare in children but common in middle-aged and old males [1]. Prostatic calculi are almost associated with benign prostatic hyperplasia (BPH) or chronic prostatitis, and some papers have reported that they do not influence the level of prostate specific antigen (PSA) in men without clinically detectable prostatitis. Seldomly, although there is no certain association between them, moreover they may be present in association with prostate cancer [2]. They are associated with chronic inflammation, epithelial damage, and obstruction of the glandular tissue on histological examination. However, the clinical significance of prostatic calculi is unknown. Prostatic calculi are asymptomatic in most cases, but large calculi may lead to urinary retention, prostatitis, or chronic pelvic pain syndrome. It has been reported that a prostatic calculus is actually a cluster of bacteria and that these calculi may be the cause of prolonged bacteriosis in patients with recurrent urinary tract infections [3]. In the literature, giant prostatic urethral stones were rare in males particularly before the sixth decade [4].

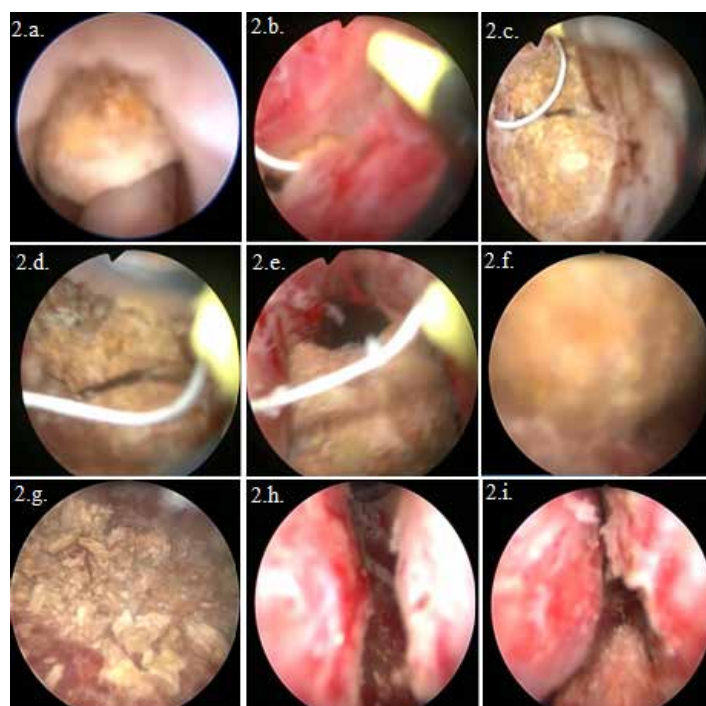
## Case Report

A 44-year-old man presented with urgency, frequency and strangury. These symptoms have persisted for about three years. His digital rectal examination revealed a moderately enlarged peripheral soft prostate gland and with stony hard consistency in some inner areas, but not fixed as a tumor nodule. Prostate-specific antigen (PSA) was 0,47 ng/dL. Creatinin was within normal limits. His urinary sediment demonstrated microscopic hematuria and pyuria, and his urine was infected with ESBL (+) E.Coli. The infection was treated with a 1gr meropenem IV every eight hours for a week and after treatment, the control culture was sterile. An examination of the kidneys, ureter, and bladder (KUB), X-ray study, and CT scan (Figure 1 ) revealed two giant prostatic urethral stones, each greater than 2.5 cm in size. The upper urinary tract and bladder appeared to be normal in CT. We decided not to plan a biopsy because there was no nodule determined by digital rectal examination. Also, a CT scan secondary to erythrocytosis in urinary sediment showed us prostatic urethral calculi and our young patient had low PSA level. The patient underwent cystourethroscopy. Cystourethroscopy revealed almost complete closure of the prostatic urethra by the giant stones. Two giant prostatic urethral stones were removed endoscopically (Figure 2). We made only minimal resection of the left lobe of the prostate to extract the stone, but we did not make complete resection of the prostate because the patient did not accept it before the operation. He only wanted us to extract the stones because of his age and probable complications, especially retrograde ejaculation. In addition, we decide to follow up his uroflowmetry because, after stone extraction, cystourethroscopy revealed that the prostate was moderately small, and the prostatic

urethra was open. After surgery, a urethral catheter was placed. After the urethral catheter was taken on the postoperative second day, the patient voided with a good stream. During the first month of operation, the patient had no complaints regarding his voiding pattern. His urine culture remained sterile. Ultrasonography and X-ray examinations revealed no remaining calculi in the lower urinary tract. His post-operative period was uneventful and he was started on alpha-1A blocker in the postoperative period because of his uroflowmetric patterns and international prostate symptom score. His average flow was 10.7ml/sec and maximal flow was 14.3 ml/sec. His international prostate symptom score was 14. We did not take uroflowmetry measurement before the operation because of urethral stones and the patient urinating drop by drop. At follow-up during the first month after the surgery, the patient emptied with a good stream.



**Figure 1.** a. KUB showing giant prostatic urethral stones (preop), b.,c.,d. Unenhanced CT scan showing gland with giant stones., e. KUB : postop stone free image, f. Postop fragmented Stones



**Figure 2.** Cystoscopic images

## Discussion

Prostatic calculi are usually subclinical, but if inflammation is present along with the calculi, various symptoms of the lower urinary tract can be present. Shoskes et al. [5] found that prostatic calculi were generally identified in patients with chronic prostatitis and postulated that because of the presence of prostatic calculi, there was more inflammation in the prostates of these men and that these men had to strain more to urinate than men without prostatic calculi.

Prostate calculi were commonly reported to be asymptomatic in most cases, and some papers have reported that these calculi are actually a cluster of bacteria and may cause urinary tract infections. Most articles have reported that the degree of LUTS may be relative to the presence of large prostatic calculi and inflammation [6]. Although prostatic calculi are relatively common, and complications are rare [4]. Less than 20 cases of giant prostatic calculi have been reported in the literature. They occur more frequently in younger men, unlike microscopic prostatic calculi, which are usually seen in men above the age of 50. Patients can present with lower urinary tract symptoms, urinary retention, pain, and urethral strictures. The etiology of prostatic calculi is not clear. It is generally accepted that prostatic calculi are part of the normal process of aging and only rarely may have clinical importance [7]. True prostate calculi are formed by deposition of calcareous material on corpora amylacea [4]. The pathogenesis of the formation of prostate calculi is thought to be the deposition of hydroxyapatite crystals in corpora amylacea, which is assembled by desquamation of aciner cells and stasis of prostatic fluid following obstruction of prostate ducts. Prostatitis is implicated as one of the predisposing causes that initiate the cascade of prostatic calculi formation. Chronic prostatitis and recurrent urinary tract infections have been implicated in their development. Such infection and stasis likely result in increased pressure and often results in "autoprostatectomy" of the prostate tissue. Enucleation of the gland is therefore seldom necessary as part of stone management. In the current patient, the stone composition was calcium phosphate and calcium carbonate; similar chemical compositions have been reported for other giant prostatic calculi [8]. Prostatic calculi have also been reported in association with ochronosis, hemospermia, hyperparathyroidism, prostatic hyperplasia and carcinoma in the literature. Kamai et al. [4] reported sudden urinary retention in a 70-year-old man with giant prostatic calculi. Since the patient had no prior history of any known predisposing diseases, such as urethral stricture, prostatic hyperplasia and chronic prostatitis, they suggested a congenital diverticulum in the prostatic urethra or a persistent utricle as the cause of giant prostatic stones. Since the present case provides no history of common predisposing factors such as congenital diverticulum or persistent utricle, it could be stated that this is a possible cause, as well. However, endoscopy remained unrevealing for any anatomic abnormality in the lower urinary tract. Management techniques for giant prostatic calculi have included radical prostatectomy, cystotomy with bladder neck incision, and endoscopic lithotripsy [8]. Since the endoscopic approach is the first choice in our case, the patient underwent endoscopic lithotripsy without removing prostate tissue,

multiple giant prostatic urethral stones were removed using the endoscopic urethral route.

## Conclusion

Giant prostatic calculi are uncommon and usually associated with obstruction voiding, and are easy to diagnose. The infrared analysis revealed that the majority of the prostatic calculi are mainly composed of calcium phosphates. Several management techniques for giant calculi were described. Enucleation of the gland is therefore seldom necessary as part of stone management. We performed a successful treatment using a single-step endo-urological intervention with holmium-YAG laser lithotripsy.

## Scientific Responsibility Statement

The authors declare that they are responsible for the article's scientific content including study design, data collection, analysis and interpretation, writing, some of the main line, or all of the preparation and scientific review of the contents and approval of the final version of the article.

## Animal and human rights statement

All procedures performed in this study were in accordance with the ethical standards of the institutional and/or national research committee and with the 1964 Helsinki declaration and its later amendments or comparable ethical standards. No animal or human studies were carried out by the authors for this article.

## Conflict of interest

None of the authors received any type of financial support that could be considered potential conflict of interest regarding the manuscript or its submission.

## References

1. Kim SH, Jung KI, Koh JS, Min KO, Cho SY, Kim HW. Lower urinary tract symptoms in benign prostatic hyperplasia patients: orchestrated by chronic prostatic inflammation and prostatic calculi? *Urol Int.* 2013;90(2):144–9.
2. Klimas R, Bennett B, Gardner WA. Prostatic calculi: a review. *Prostate.* 1985; 7(1):91–6.
3. Eykyn S, Bultitude MI, Mayo ME, Lloyd-Davies RW. Prostatic calculi as a source of recurrent bacteriuria in the male. *Br J Urol.* 1974;46:527–32.
4. Kamai T, Toma T, Kano H, Ishiwata D. Urethral obstruction due to protruding prostatic calculi. *J Urol.* 1999; 162:163–4.
5. Shoskes DA, Lee CT, Murphy D, Kefer J, Wood HM. Incidence and significance of prostatic stones in men with chronic prostatitis/chronic pelvic pain syndrome. *Urology.* 2007;70(2):235–8.
6. Gandaglia G, Briganti A, Gontero P, Mondaini N, Novara G, Salonia A, et al. The role of chronic prostatic inflammation in the pathogenesis and progression of benign prostatic hyperplasia (BPH). *BJU Int.* 2013;112(4):432–41.
7. Sondergaard G, Venter M, Christensen PO. Prostatic calculi. *Acta Pathol Microbiol Immunol Scand.* 1987; 95(3):141–5.
8. Bedir S, Kilciler M, Akay O, Erdemir F, Avci A, Ozgök Y. Endoscopic treatment of multiple prostatic calculi causing urinary retention. *Int J Urol.* 2005;12:693–5.

## How to cite this article:

Aydemir Asdemir, Esat Korgali, Huseyin Saygin, Tugba Yildiz Asdemir. Giant prostatic urethral stones in a young patient. *Ann Clin Anal Med* 2021;12(Suppl 2): S233-235